

# Orthopedic Appliance Company

Asheville, NC • 828-254-6305 • www.OrthopedicApplianceCo.com

Prosthetics • Orthopedic Bracing • Seating & Mobility

No. 10

## From Amputation to Ambulation

The diagnosis construction worker Kyle J., 38, received in mid-2008 was troubling: MRSA\*, the antibiotic-resistant staph infection that can be fatal, had developed in an open sore on his left foot and spread up his leg. By the time the Type II diabetes patient (already challenged by a prior mid-metatarsal amputation of his right foot) obtained appropriate treatment, the infection was out of control, leading ultimately to transtibial removal of his left leg.

Kyle's amputation and course of rehabilitation provide an excellent illustration of the process a new amputee follows from limb removal surgery to a successful return to ambulatory mobility.

Not all amputees achieve prosthetic success, of course: Many factors can limit their ambulation potential and motivation—age, poor health, lack of vitality and various psychological factors, among others. However, those who successfully resume their pre-limb-loss lifestyle do so after completing a well-defined process generally involving doctors (usually the amputee's personal physician, the amputating surgeon and sometimes a physiatrist), a physical and/or occupational therapist, perhaps a nurse and/or social worker, and of course, a well-qualified prosthetist. This article reviews the typical mileposts a lower-limb amputee passes on the road to a successful prosthetic outcome.

\* MRSA - methicillin-resistant *Staphylococcus aureus*

•••••

Kyle awoke from his surgery with a removable rigid dressing covering his amputation wound. A few days later, a pylon and prosthetic foot were added, providing a platform for early weight-bearing and facilitating exercise. Before leaving the hospital, Kyle received initial physical therapy and a follow-up visit from his prosthetist, who would engineer his return to an ambulatory lifestyle.

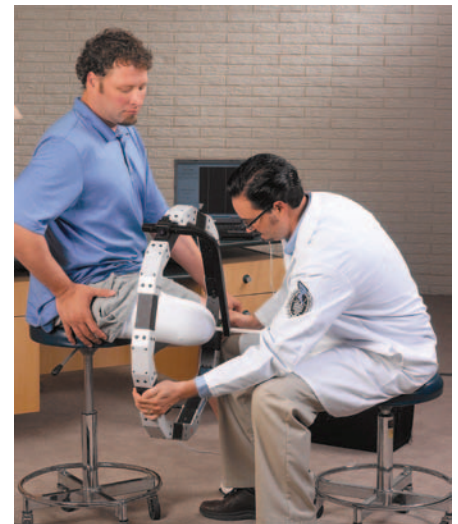### Referral & Initial Care

*In an ideal world, prosthetic intervention would begin before amputation with the prosthetist interacting with the patient to answer questions and relieve anxiety and taking part in discussions*

**Prosthetics Today**

*regarding amputation level, type of post-surgical dressing to be used, anticipated complications, and patient and family expectations. As a practical matter, such early involvement is often not feasible, and the prosthetist's involvement begins a few—or many—days after limb removal.*

*Once amputation level is determined, an ensuing decision involves the type of dressing that will cover the wound, a choice that can have significant prosthetic implications.*



**CAD/CAM scanning systems such as the Omega TracerCAD create a precise digital model of the residual limb for socket fabrication.**

(Continued on page 2)

Courtesy Ohio Willow Wood



**AOPPS post-op system**  
Courtesy FLO-TECH

### Now Offering the Roll-A-Bout

Orthopedic Appliance Company is now pleased to offer the Roll-A-Bout, a four-wheeled crutch substitute that enables patients to be both mobile and 100% non-weight-bearing while recovering from lower leg injuries or surgery.

This simple-to-use mobility aid is lightweight and safe, folds flat for easy storage, and features both hand and parking brakes for sure control.

Choosing the Roll-A-Bout over a wheelchair for appropriate patients helps maintain cardiovascular fitness, muscle tone and balance as well as personal independence and freedom to move about both home and community.

The Roll-A-Bout is commonly prescribed for heel spurs, diabetic ulcers, infections, fractures, dislocations, Charcot foot, ruptured tendons, sprained ankles, and post-operative protection of the lower limb.

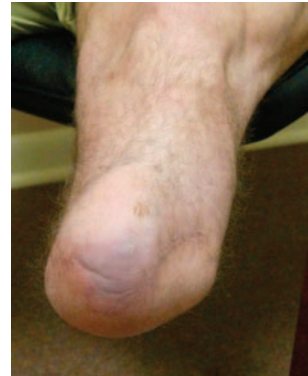For additional information on the Roll-A-Bout, call us at 1-828-254-6305.



# The Prosthetic Process – Stepping Stones to Restored Mobility

(Continued from page 1)

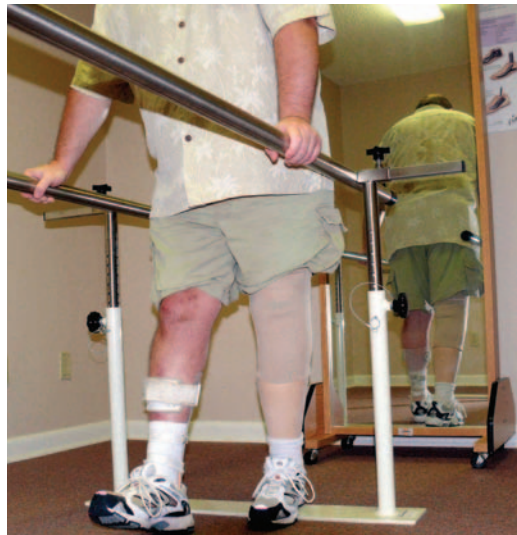The conservative soft dressing is sometimes still used, particularly for older, dysvascular patients, because it allows frequent observation of the site. From a rehabilitation standpoint this choice is less than ideal, because it slows healing, reduces edema control, increases risk of contractures, and delays the start of prosthetic management.



**Tender tissue at distal end of Kyle's residual limb led to prescribing a custom gel liner for advanced protection.**

Generally considered preferable from the prosthetist's viewpoint is the rigid dressing, which though minimizing opportunity for frequent wound inspection effectively controls edema, speeds healing and reduces pain while also protecting the wound. When combined with a simple pylon and foot, the rigid dressing enables the amputee to begin partial weight-bearing and exercising his residual limb almost immediately (thus the name immediate post-operative prosthesis or IPOP).

Between these extremes the custom removable rigid dressing and prefabricated options such as the APOPPS (Adjustable Post-Operative Protective & Preparatory System) offer compromise solutions that enable both wound inspection and reasonably early weight-bearing. Even if not involved before the amputation, the prosthetist can still initiate early intervention if the referral is made while the patient is still in the hospital. The sooner the prosthetist and therapists working with the new amputee can coordinate their efforts, the better.



**Gait training—Key ingredient for regaining ambulatory mobility.**

A week after his surgery Kyle took his first step on a basic pylon and prosthetic foot attached to his removable rigid dressing. Two weeks later his staples were removed, and he was discharged to continue his rehabilitation as an outpatient. His first appointment included a complete prosthetic exam, consisting of a detailed personal medical history, analysis of his overall state of health and residual limb capabilities, and assessment of his prospective ambulatory potential. Through this evaluation process, Kyle was found to meet the criteria of Functional Level K-3 in the Centers for Medicare and Medical Services' standards for establishing medical necessity.

**K3—Functional Level 3: Patient has the ability or potential for ambulation with variable cadence. Typical of the community ambulator who has the ability to traverse most environmental barriers and may have vocational, therapeutic or exercise activity that demands prosthetic utilization beyond simple locomotion.**

At that point, Kyle and his prosthetist proceeded to formulate realistic prosthetic and lifestyle goals for him.

## Evaluation & Assessment

A comprehensive initial evaluation and assessment of a new amputee's ambulation potential are key to a successful outcome and appropriate expenditure of health care resources. The prosthetist needs to know how well the residual limb will bear up under the stresses of weight-bearing and whether the patient's overall state of health and other medical issues will limit his or her ability to use a prosthesis effectively.

For various reasons, including limited range of motion, generalized weakness, and inability to bear weight on the residual limb due to size, shape and/or pain issues, this evaluation may reveal a new amputee will receive relatively little benefit from a functional prosthesis. In such instances a simple cosmetic device or no prosthesis at all is sometimes the most appropriate choice. At the opposite end of the spectrum are younger, otherwise healthy amputees who are candidates for sophisticated, high-capability replacement limbs.

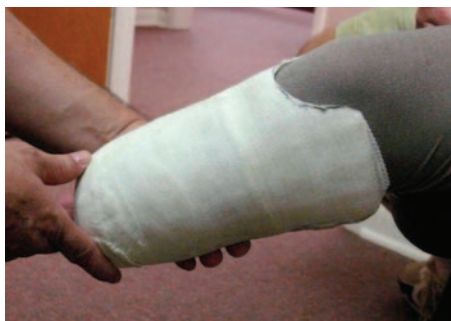During the initial visit with his prosthetist, Kyle was measured for his preparatory (or "training") prosthesis, a temporary leg he would use for several months while the size and shape of his residual limb stabilized and he learned to walk on a prosthetic limb. The preparatory limb, consisting of a custom socket, pylon and basic prosthetic foot, enabled him to continue gait training with his therapist, which had begun soon after surgery.

Over subsequent weeks, as his walking proficiency improved and his residual limb volume continued to decrease, Kyle revisited his prosthetist several times for socket modification and alignment adjustment—important steps along the road to optimizing his gait. Four months later, with his residual limb volume stabilized and his gait training progress indicating he was nearing his goal of becoming a community ambulator, Kyle was ready to progress to his definitive limb.

## Preparatory Phase

As its name suggests, the function of a preparatory, or training, prosthesis is to help a new amputee transition to a new life of walking on an artificial limb. This is typically an adjustable system prosthetists can adapt to patients while they are learning a new way of walking and managing change in their residual limb.

The preparatory prosthesis also helps the clinical team determine the amputee's ultimate ambulation potential and the most appropriate components for the permanent system.



**Fiberglass cast creates image of residual limb for fabricating prosthetic socket.**



**Check sockets enable prosthetists to view residual limb in "working" environment.**

Patients normally wear their preparatory prosthesis for 3-6 months. During this period, prosthetist and therapist can interact to help the amputee adjust to his or her maturing residual limb and other physical changes. Several fit and alignment adjustments are normally made during this period as residual limb edema subsides and the patient's gait becomes more efficient.

With Kyle's ongoing susceptibility to neuropathy and MRSA recurrence, his prosthetist determined advanced protection was indicated for the residual limb, notably the compromised tissues surrounding the amputation site. A total-surface-bearing (hydrostatic) socket design was selected with suction suspension achieved with the aid of a custom-fabricated gel liner. The prosthesis was completed with a lightweight pylon and dynamic-response foot.

Starting with a cast impression of Kyle's nearly mature residual limb, his prosthetist made appropriate modifications to ensure total contact, then fashioned a transparent check socket with which the degree of total contact and areas of undesirable pressure distribution could be visualized and corrected. After socket modification, the remaining components were attached and a cosmetic skin added to complete the prosthesis.

## The Definitive Prosthesis

Selecting the most appropriate componentry for a new amputee's specific needs and abilities is an essential part of the prosthetic process. After a careful preparatory phase, the definitive prosthesis is fabricated using more permanent materials and incorporating all knowledge gained to date.



**Vacuum forming a socket over mold of a residual limb.**

Courtesy Otto Bock HealthCare

Various factors must be weighed in making the prosthetic prescription;

- the condition and weight-bearing ability of the residual limb;
- the patient's overall health, activity level, vocational needs and expectations;
- the type of suspension most appropriate for the amputee;

- specific components to be used, including socket, foot, pylon and (if applicable) knee unit;
- cosmetic finishing, and
- cost and funding.

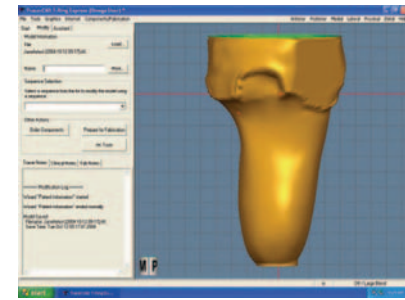
Designing and building a definitive prosthesis is an art, requiring knowledge, skill and experience.

Traditionally, socket design and fabrication have been primarily manual procedures; however, CAD/CAM (computer-aided design/computer-aided manufacturing) systems are now increasingly being used to streamline the process.

Starting with information from a direct scan or negative cast of the residual limb, CAD/CAM software presents a visual image of the limb from which the prosthetist can design a socket on a monitor, optimizing the overall shape and trimlines and adding build-ups and reliefs as necessary. Finally, the CAD/CAM system feeds the design to a carver, which that creates a positive model over which the shell of the definitive socket can be vacuum-formed.

Once Kyle's definitive limb was fabricated, the next step was fine-tuning the fit and alignment of the system to achieve optimum functional performance, comfort and safety. After ensuring the socket fit properly and testing the suspension, Kyle's prosthetist evaluated the static alignment, noting the length and angulation of the prosthesis as Kyle stood upright and relaxed. Next came dynamic alignment involving careful analysis of Kyle's gait and making adjustments to optimize function, maximize comfort and minimize energy expenditure.

(Continued on page 4)



**CAD/CAM software allows prosthetists to rectify socket designs with mouse and keyboard.**

Courtesy Ohio Willow Wood



**CAD/CAM carver brings digital precision to forming socket molds.**

Courtesy Otto Bock HealthCare



**Demonstrating correct technique for donning Kyle's custom gel liner.**

## Note to Our Readers

Mention of specific products in our newsletter neither constitutes endorsement nor implies that we will recommend selection of those particular products for use with any particular patient or application. We offer this information to enhance professional and individual understanding of the orthotic and prosthetic disciplines and the experience and capabilities of our practice.

We gratefully acknowledge the assistance of the following resources used in compiling this issue:

FLO-TECH • Ohio Willow Wood • Otto Bock Health Care

# Improved Orthopedic Appliance Co. Website up and Running

Orthopedic Appliance Company has unveiled its new and improved web site at [www.orthopedicappliaceco.com](http://www.orthopedicappliaceco.com). Our new comprehensive site presents a wealth of information about prosthetic and orthotic rehabilitation and durable medical equipment, tailored to the needs of physicians, therapists, case managers, nurses, administrators, other referral sources, and of course patients, their family members and caregivers.

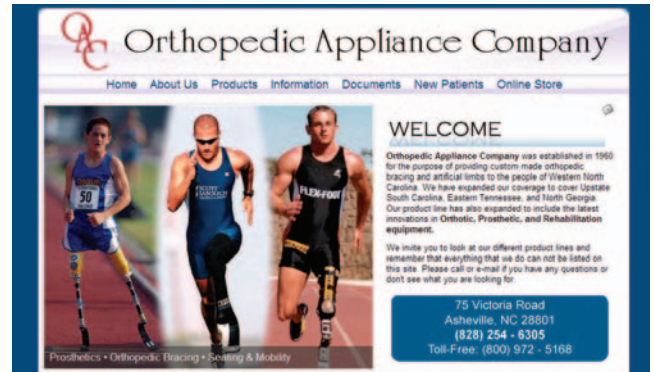New patients, for example, can learn about our practice history and staff and download directions to our office, insurance information, and new patient forms, which can now be easily printed and filled out in

advance of the first office visit. An in-depth Products section presents a detailed, illustrated list of the various appliances and patient aids we offer. Some off-the-shelf items can be purchased directly through our new Online Store.

With a click of their mouse, site visitors can also access patient testimonials, patient instructions for various orthotic appliances we provide, and an archive of our recent newsletters.

We hope you find the new OAC website to be beneficial

and welcome your comments and suggestions. Just click on About Us and Contact Us and send us your thoughts.

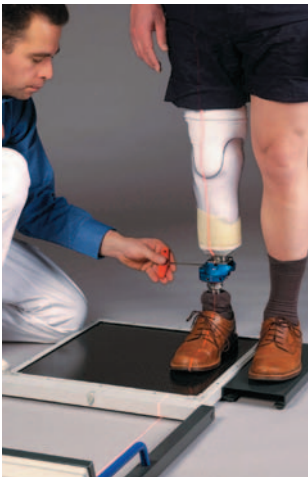

## Final Steps Critical to Prosthetic Success

(Continued from page 3)

### Fitting & Alignment

“Fit” refers to the quality of the interface between the socket and residual limb. “Alignment” is the important relationship of the socket, ankle and foot in a below-knee prosthesis (adding the knee for an above-knee limb). Because a unilateral lower-limb amputee expends an estimated 40 percent more energy walking than a person without limb loss, it is essential that the limb function with optimal efficiency.



**LASAR Posture alignment system.**

Courtesy Otto Bock HealthCare

Transparent check (or test) sockets can greatly enhance the ultimate socket fit, because they allow our prosthetic team to view the residual limb inside the socket while the patient is walking. Discovering areas of excessive pressure and less than total contact

with a check socket enables prosthetists to make corrections throughout the fitting process and thereby reduce the risk of skin breakdown, pistoning, discomfort and other problems that would likely limit the patient’s outcome.

Alignment is corrected as necessary in response to new components introduced or changes in physical condition. The prosthetist adjusts the positioning of the lower components in relation to the socket to provide the best-possible balance, comfort, gait pattern, energy efficiency and cosmesis. Traditional mechanical methods are now being enhanced by advanced laser and digital equipment that bring new simplicity and precision to the alignment process. Once the alignment is

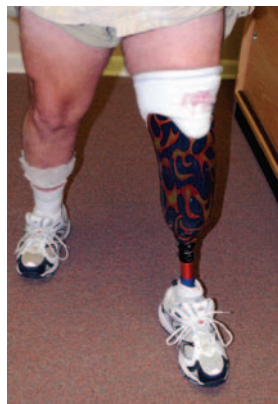completed, cosmetic finishing can be applied if desired, and the prosthetic leg is ready to go. . . . .

By the time Kyle received his definitive new leg, he was close to achieving his goal activities: to be able to wear his prosthetic leg for the better part of each day and to ambulate effectively at home and in the community. Though no longer able to perform rigorous construction functions, he has a good understanding of his limitations and is returning to school to learn a less physically demanding skill. Every few months, he will return for prosthetic follow-up visits, during which adjustments for further residual limb changes and wear-and-tear concerns can be accomplished.

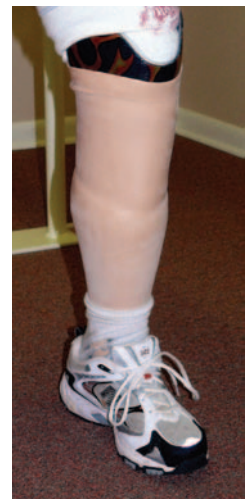### Follow-up & Maintenance

Initially, after receiving their permanent prosthesis, new amputees usually return to their prosthetist frequently for adjustments and to pose questions that become evident as they gain endurance and “spread their wings.”

After a few months, the need for return visits typically declines to once every 3-4 months. Follow-up visits address any problems the amputee may be having and routine maintenance, cleaning and replacement of mechanical and electronic components. Follow-up is a lifelong activity.



**Kyle walks confidently in his definitive prosthesis.**



**Kyle’s finished prosthetic limb with cosmetic skin applied.**

Our well-qualified staff is prepared to escort amputees through the prosthetic process and help them achieve the ultimate functional outcome of which they are capable. We welcome your inquiries about any aspect of prosthetic care or management options for specific patients.